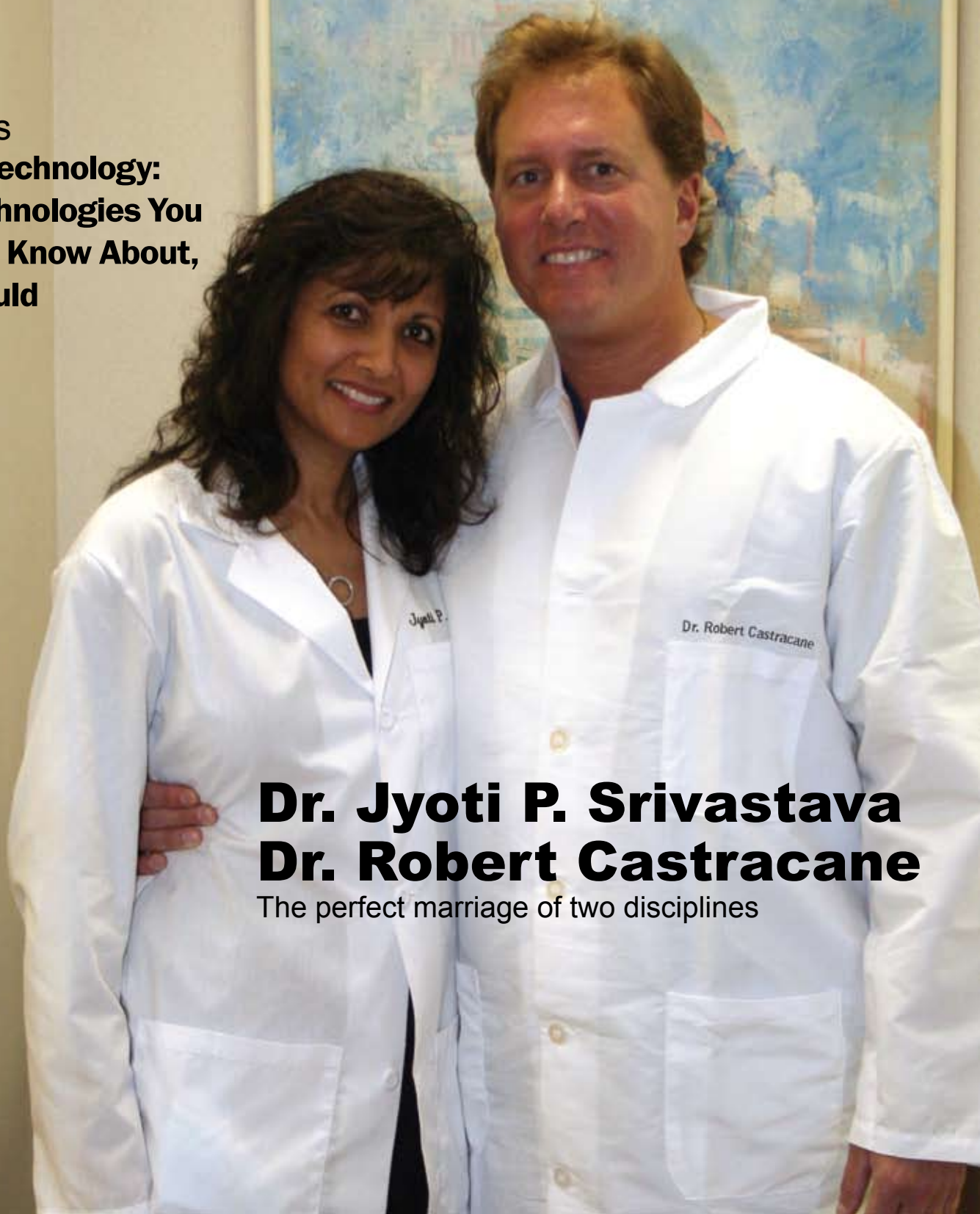

# DOCTOR *of* DENTISTRY

A BUSINESS AND LIFESTYLE MAGAZINE FOR DENTISTS

Features

**Dental Technology:  
Five Technologies You  
May Not Know About,  
But Should**



**Dr. Jyoti P. Srivastava**  
**Dr. Robert Castracane**

The perfect marriage of two disciplines



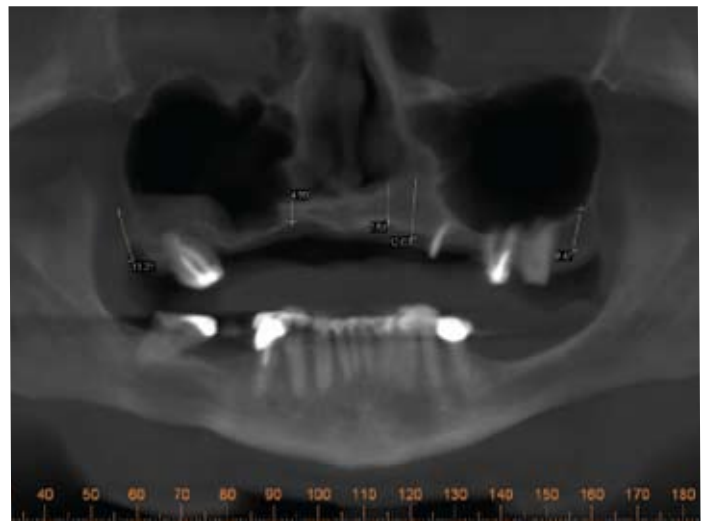
## Dental Restoration Achieved with a Combination Approach

by Andrei Mark, D.D.S., Board Certified Oral & Maxillofacial Surgery

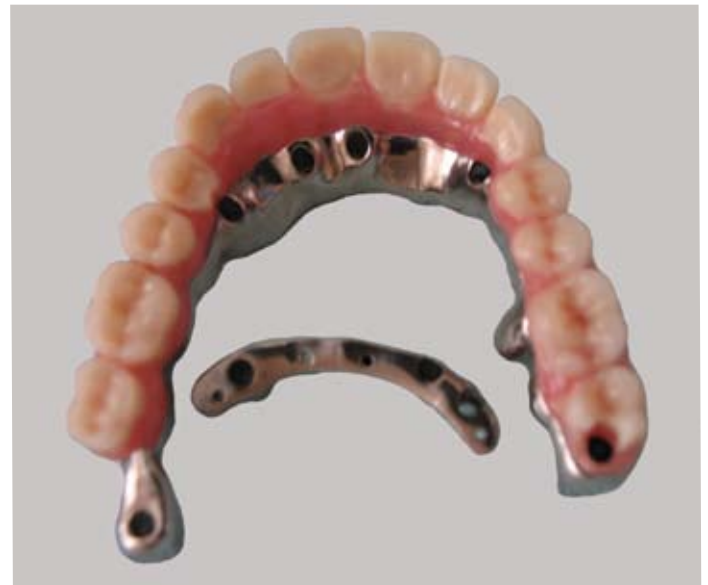A 67-year-old female presented to the office for a consultation regarding her loose maxillary denture on a severely atrophic alveolus. She had been wearing a denture for many, many years. The denture was retained by telescopic sleeves over several teeth in very poor condition. Tooth number 2 was completely loose; however, the patient insisted on maintaining it because it was stabilizing the denture. Tooth number 12, 14 and 15 were still in her mouth. As protocol, I always take a CT scan with an i-CAT imaging system. After reviewing her CAT scan, I explained to her that bilateral sinus lifts would be the ideal approach for her situation. The patient understood her options, but refused a sinus lift bone graft and requested that an alternative procedure be performed first to stabilize her maxillary prosthesis without bone grafts. She did agree that if we were not successful without the sinus lifts, that she would consider having the sinus lifts in the future.

The treatment plan ultimately consisted of placing implants in the atrophic anterior maxillary where small areas of bone were identified between the oral and nasal cavities. In addition, we chose to place pterygoid plate implants in position number 1 and 16. We also elected to maintain teeth number 12, 14 and 15, since they were very stable and we were unsure of the success of the implants without performing a sinus lift.

The surgery went smoothly and was uneventful. The implants were placed in position number 1, number 6, number 10, and number 11 respectively. These implants were placed as a two-stage procedure and her denture was relined. The patient was able to wear her denture the whole time while the implants were healing.



Pre-Op i-CAT



Fixed hybrid bridge with anterior milled bar by Marotta Dental Studio.

The patient returned to my office after approximately three months and the implants were uncovered and

healing screws were placed. It was at that time that the brainstorming began.

How to restore a combination of implants and natural teeth with a fixed prosthesis? We decided on making gold copings on the remaining natural teeth, connecting the anterior implants with a bar that was milled to be parallel to the copings on the natural teeth. The implants in position 1 and 16 were restored by using a direct screw-in technique.

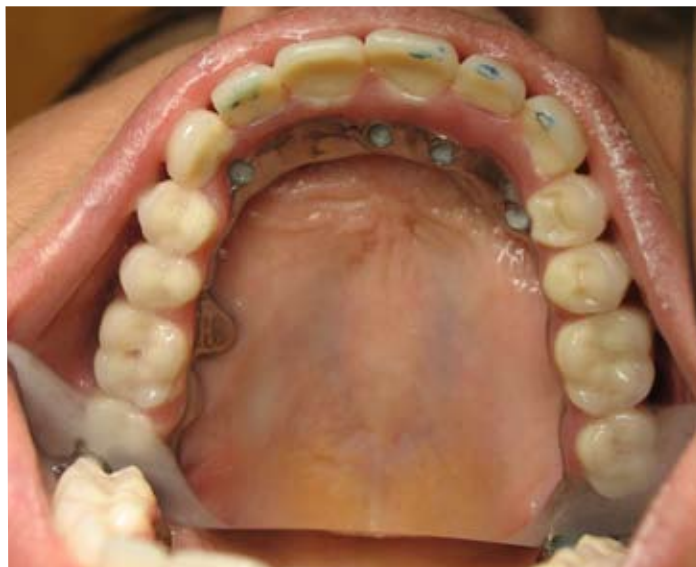As you can see from the photo (see figure 1) a combination denture with a milled bar was obtained from Marotta Dental Studio. First, the copings were made on the natural teeth and permanently cemented. Second, the anterior maxillary bar was screwed into the three anterior implants. Then the prosthesis, with denture teeth processed into it was placed over the copings and the anterior bar. Once seated fully, the retaining screws were screwed into implant number 1 and number 16. Then retaining screws were screwed into the anterior bar.

This combination of telescopic copings, anterior milled bar along with two implants screwed directly into the metal frame with denture teeth baked into it provided all the characteristics needed for this restoration. It became retrievable, the anterior implants were stabilized, the natural teeth were protected by the telescopic copings and the prosthesis was fixed rather than removable.

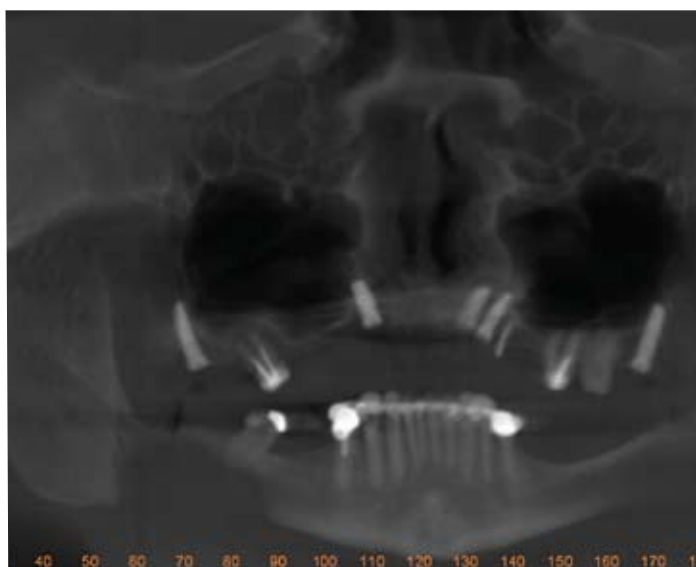This procedure satisfied all of patient's requirements, replaced the missing teeth and the missing alveolar process, thus fully supporting the lip. The prosthesis is able to be cleaned and the patient will use appropriate oral hygiene to maintain it.

While at first blush this appears to be a complicated prosthesis, when broken down into its smaller components, each one of the elements is a simple technique that was combined to create one single prosthetic solution. Important lessons from this restoration are: you have to listen to the patient's needs, you have to have a great lab like Marotta Dental Studio that can execute such a complex restoration, and you must have great teamwork between the oral surgeon and restorative dentist in order to achieve success.

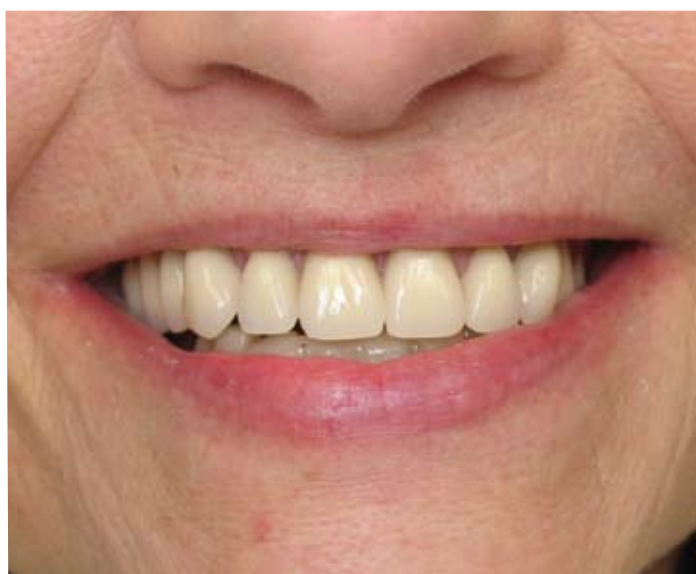Contact Dr. Andrei Mark at Central Park Oral Surgery at [amark@cpoms.com](mailto:amark@cpoms.com) or by phone at 212-813-0707.



Intraoral view showing four retention screws palatal to anterior teeth.



Post-Op i-CAT



Final restoration by Dr. Steve Tushman.